

Original article

DIAGNOSTIC CONCORDANCE CHARACTERISTICS OF OROFACIAL LESIONS SEEN IN LAGOS UNIVERSITY TEACHING HOSPITAL

Emeka CI,² Effiom OA,¹ Gbotolorun OM,² Oluwakuyide R,¹ Adeyemi MO,² Olojede AC,² Odukoya O¹

¹Department of Oral and Maxillofacial Pathology/Biology, College of Medicine, University of Lagos

²Department of Oral and Maxillofacial Surgery, College of Medicine, University of Lagos

ABSTRACT

OBJECTIVE: This study aimed to compare clinical diagnosis with histopathologic diagnosis of orofacial lesions.

METHODS: Clinical and histopathological reports from orofacial biopsy records (2009 to 2013) of the Departments of Oral and Maxillofacial Pathology / Biology, and Oral and Maxillofacial Surgery clinic, Lagos University Teaching Hospital (LUTH) were retrieved. Data analyzed were patients' gender, age, orofacial sites, clinical and histopathological (incisional and excisional) diagnoses of biopsied orofacial lesions. The lesions were classified into: odontogenic cysts (OC), non-odontogenic cysts (NOC), odontogenic tumours (OT), non-odontogenic tumours (NOT), and malignant tumours (MT). For each patient, clinical diagnosis was matched with histopathologic diagnosis, and concordance was calculated using kappa value (κ), which were rated as: Poor = 0.0-0.4, good = 0.41- 0.7, very good = 0.71- 0.8, excellent = 0.81-1.

RESULTS: From a total of 620 cases, histopathologic diagnosis did not match in 35.5% but matched in 64.5% ($\kappa = 0.45$ and CI = 0.65). The highest misdiagnosis rate of 44.5% was observed in NOT, followed by NOC (37.0%), OC (35.7%), OT (29.6%) and MT (25.7%). With $\kappa = 0.45$ and CI = 0.65, the diagnostic concordance in this study was good. Clinicians in this study, were however more accurate in the diagnosis of malignant tumours ($k = 0.65$) and odontogenic tumours ($k = 0.58$).

CONCLUSION: The rate of clinical misdiagnosis among clinicians in LUTH though low can be improved. We recommend improvement in diagnostic skills in dental practice by continuous training in recent clinical and histopathological diagnostic techniques. Also, affordable and accessible pathology support services should be provided to general dentists / general dental practitioners and dental specialists in Nigeria.

Correspondence address:

Dr O A Effiom

Department of Oral & Maxillofacial Pathology /Biology,
Faculty of Dentistry, College of Medicine, University of Lagos
jumokeffiom@yahoo.com
+2347032723808

Keywords: Concordance, Orofacial lesions, Diagnosis

INTRODUCTION

The maxillofacial region is a common anatomic site for the development of numerous lesions that may be odontogenic and non -odontogenic tumours, cysts, infections and mucosal lesions. For this reason, clinical diagnosis of these various lesions may be challenging.^{1,2} Accurate and definitive diagnosis of disease can be obtained through the cooperation of the clinician and pathologist by combining initial clinical diagnosis, imaging, laboratory investigation and finally histopathological evaluation, which is the gold standard for diagnostic oral pathology. The assessment of the relationship/concordance between clinical and histopathological diagnoses of orofacial disease in the oral and maxillofacial region is therefore necessary in clinical practice.

To achieve effective and appropriate management of any disease, there must be prompt disease detection and accurate diagnosis. This would not only improve patient quality of life but would in addition reduce patient morbidity and mortality.³ Regarding diagnostic consistency, the relationship between the clinical diagnoses and histopathological report of lesions has been evaluated in previous studies.^{4,5} Hosseinpour et al⁴ reported 81.2% consistency between clinical diagnoses and histopathological reports. They observed the highest concordance for lichen planus, inflammatory fibrous hyperplasia and leukoplakia and the lowest concordance for pemphigus, squamous cell carcinoma and systemic lupus erythematosus; while Ghasemimoridani et al,⁵ observed the highest concordance for lichen planus and mucocele.

Although the assessment of concordance between clinical and histopathologic diagnosis of orofacial diseases is critical, perusal of the scientific literature shows a dearth in published studies on concordance of orofacial diseases in the Nigerian scientific literature. This study evaluates the diagnostic concordance characteristics of orofacial lesions diagnosed in a tertiary Nigerian teaching hospital, by comparing the clinical diagnosis with histopathologic diagnoses of the orofacial lesions.

MATERIALS AND METHODS

This study retrospectively analyzed all clinical and histopathological reports of patients seen in the orofacial biopsy service of the Departments of Oral and Maxillofacial Pathology/Biology, and Oral and Maxillofacial Surgery of Lagos University Teaching Hospital between 2009 and 2013. Data which comprised of patients' age and gender, location of orofacial lesion, clinical diagnoses and histological diagnoses were retrieved. Patients with inadequate information on the aforementioned data were excluded from the study.

The orofacial lesions were classified into six groups as odontogenic cysts (OC), non-odontogenic cysts (NOC), odontogenic tumours (OT), non-odontogenic tumours (NOT), malignant tumours (MT) and precancerous lesions (PML),⁶ and were further subdivided into three groups expressing prognostic implications as benign, precancerous, and malignant.⁶ The initial clinical diagnoses were compared with histopathologic diagnoses obtained from both incisional and excisional biopsies of the lesions. Kappa coefficient (κ) between the clinical and histopathologic diagnosis of orofacial lesions was calculated. Cohen's kappa coefficient (κ) is a statistical measure of interrater agreement for categorical items. It was used to measure the agreement between surgeon and pathologist.⁶ In general, the following scale was used to calculate concordance using Kappa values (Poor = .0-0.4, good = 0.41-0.7, very good = 0.71-0.8, excellent = 0.81-1).⁷ Data collected were analyzed statistically using SPSS version 17.0 software (SPSS Inc., Chicago, IL).

RESULTS

A total of 620 records were retrieved and used for the study. Of the 620, three hundred and two cases (48.7%) were females and three hundred and eighteen (51.3%) were males (Fig 1). The mean age was 35.6 (\pm 18.5) years; 425 (68.5%) lesions were central and 195 (31.5%) were peripheral.

The histopathologic diagnosis matched with clinical diagnosis in 400 (64.5%) cases and did not match in 220 (35.5%) cases. Cases where clinical diagnosis did not match with

histopathologic diagnosis were interpreted as misdiagnosis, while cases where they matched were regarded as concordance. The proportion of malignant tumours with concordance (74.3%) was the highest. This was followed in descending order by odontogenic tumours (70.4%), odontogenic cysts (64.3%), non-odontogenic cyst (63.0%), premalignant lesion (58.3%) and non-odontogenic tumours (55.5%) [Table 1].

The diagnostic concordance measured by kappa value was 0.45. On the kappa rating scale, this was rated as good. With respect to specific class of lesions, malignant lesions ($\kappa = 0.65$), odontogenic tumors ($\kappa = 0.58$), odontogenic cyst ($\kappa = 0.45$) and non-odontogenic cysts ($\kappa = 0.41$)

had a kappa rating of good, while benign non-odontogenic tumours ($\kappa = 0.20$) and premalignant lesions ($\kappa = 0.29$) had a kappa rating of poor (Figure 2).

The diagnosis in males with k value of 0.37 was rated poor compared to k value of 0.53 in females which was rated good. Although lesions diagnosed in the maxilla with a k value of 0.50 was lower than k value of 0.65 for mandibular lesions, however κ rating for both sites was good (Table 2 and 3). In terms of prognostic implication, malignant lesions with a κ value of 0.65 had a good kappa rating while benign lesions ($\kappa = 0.39$) and premalignant lesion ($\kappa = >0.00$) had a poor kappa rating. (Figure 3)

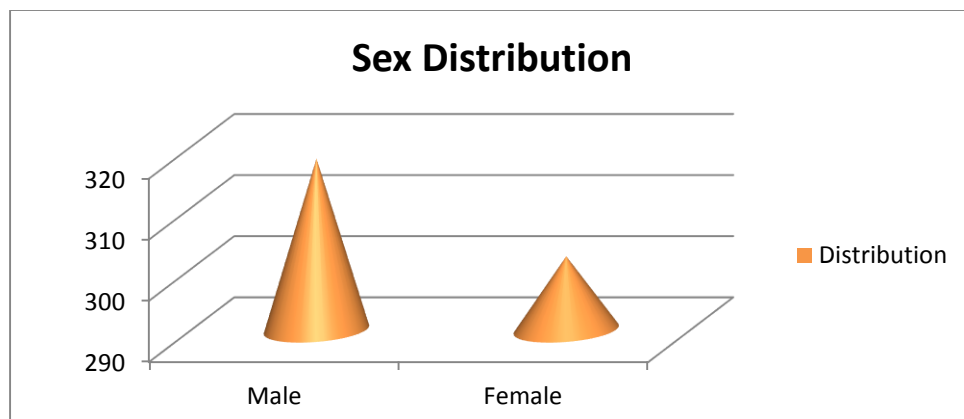


Figure 1: Gender distribution of patients with orofacial lesions

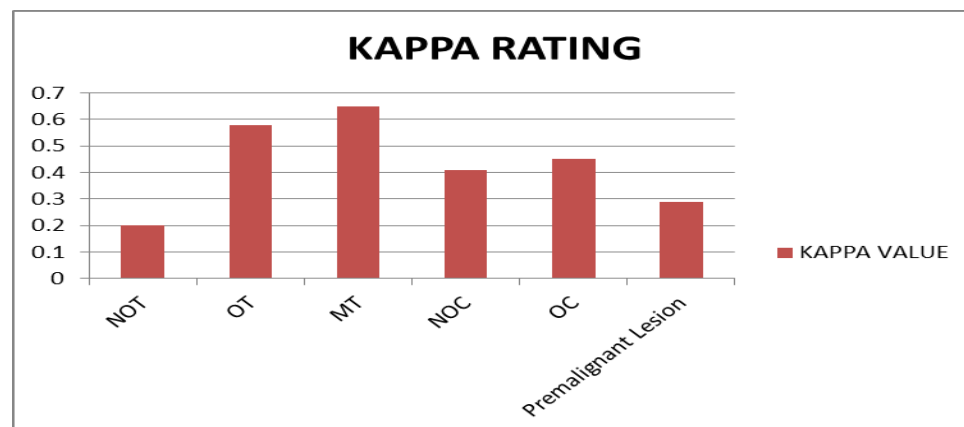


Figure 2: Kappa rating of lesions in the oral and maxillofacial region

NB: kappa Rating: Poor: 0.0 – 0.4, Good: 0.41 – 0.7, Very good: 0.71 – 0.8, Excellent: 0.81 – 1.0 Malignant tumours with concordance of 74.3% had the highest kappa value of 0.65 and a rating of good, followed by odontogenic tumors (0.58). The premalignant lesions $k = 0.29$ and non-odontogenic tumors $k = 0.20$ were rated poor.

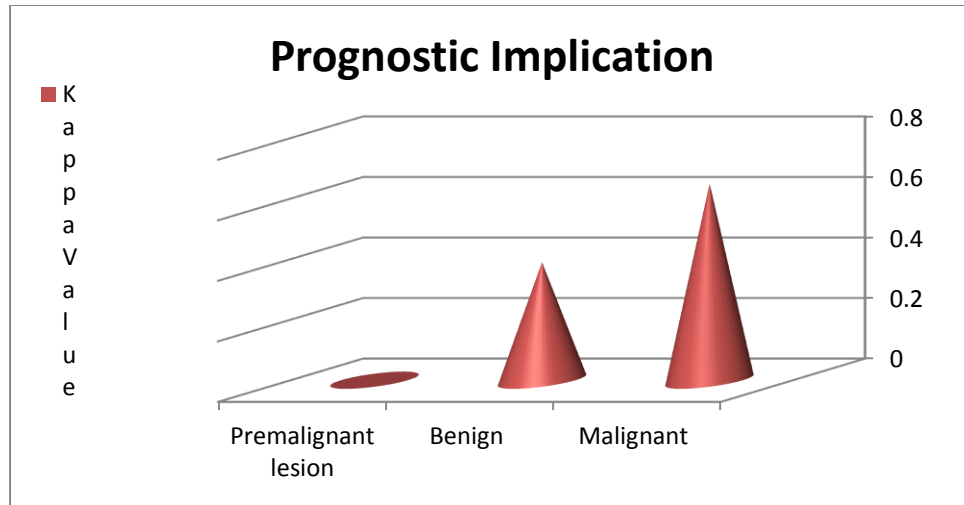


Figure 3: Prognostic implication of premalignant, benign and malignant lesions of the orofacial region

NB: In terms of prognostic implication, malignant lesions with a κ value of 0.65 had a good kappa rating while benign lesion ($\kappa = 0.39$) and premalignant lesion ($\kappa = >0.00$) had a poor kappa rating.

Table 1: showing the relationship between clinical and histological diagnosis of orofacial lesions (histological diagnosis versus concordance/dis-concordance)

Histopathological diagnosis	Concordance N(%)	Dis-concordance N(%)	Total	Total (%)	κ	P
NOT	122(55.5)	98(44.5)	220	35.5%	0.20	0.015
OT	107(70.4)	45(29.6)	152	24.5%	0.58	0.010
MT	101(74.3)	35(25.7)	136	21.9%	0.65	0.009
NOC	29(63.0)	17(37.0)	46	7.4%	0.41	0.071
OC	27(64.3)	15(35.7)	42	6.8%	0.45	0.060
PML	14(58.3)	10(41.7)	24	3.9%	0.29	0.120
Total	400(64.5)	220(35.5)	620	100%	0.45	0.003

NB: In general, histopathologic diagnosis matched with clinical diagnosis (concordance) in 400(64.5%) cases and did not match (misdiagnosis) in 220(35.5%) cases.

Table 2: Gender distribution of patients with lesions in the oral and maxillofacial region according to concordance

Gender	Concordance N(%)	Dis-concordance N(%)	Total	κ	P
Male	195(61.3)	123(38.7)	318	0.37	0.012
Female	205(67.9)	97(32.1)	302	0.53	0.018
Total	400(64.5)	220(35.5)	620	0.32	0.003

NB: In general, diagnosis in males with k value of 0.37 was rated poor compared to k value of 0.53 in females which was rated good

Table 3: Distribution of location of lesions in the oral and maxillofacial region according to concordance

Localization	Concordance N(%)	Dis-concordance N(%)	Total	κ	P
Mandible	181(74.2)	63(25.8)	244	0.65	0.032
Maxilla	154(73.0)	57(37.0)	211	0.50	0.048
Others	123(74.5)	42(25.5)	165	0.66	0.011
Total	400(64.5)	220(35.5)	620	0.45	0.026

NB: Lesions diagnosed in the maxilla with a κ value of 0.50 was lower than κ value of 0.65 for mandibular lesions; however κ rating for both sites was good.

DISCUSSION

Previous studies by Hosseinpoor et al ⁴ and Ghasemimoridani et al, ⁵ have reported a high concordance for some orofacial lesions. However, the development of strategies to minimize dis-concordance to an insignificant level was recommended to ensure accurate diagnosis and treatment of orofacial lesions. Accordingly, this study evaluated the diagnostic concordance characteristics of orofacial lesions by comparing the clinical diagnosis with histopathologic diagnoses of these lesions in a tertiary Nigerian teaching hospital and found a high concordance of 64.5%. This was relatively higher than findings from previous studies by Patel et al ³ and Williams et al, ⁸ which reported a lower diagnostic concordance of 50.6% and 56.4% respectively. The overall diagnostic concordance is considered good as indicated by kappa value of 0.45, but there is need for improvement as the value falls below the excellent kappa value which ranges between 0.81-1.0.⁷ Kappa values below the excellent range may be as a result of the differences in clinician (surgeon)/pathologist competence and quality of cooperation.

Unlike Seoane et al ⁹ that reported a high concordance value in the diagnosis of NOT, OT and precancerous lesions and low concordance value for MT, diagnostic concordance for NOT and PML in this study was poor, while clinicians were more accurate with the diagnosis of MT ($\kappa=0.65$) and OT ($\kappa=0.58$) in the clinical setting in this Centre. Perhaps clinicians' familiarity with the presentation of malignant lesions in

LUTH as compared to the recognition of the other lesions which have nonspecific presentations may be attributed to findings in this study.

There were slightly higher concordance rates for the lesions located in sites such as the tongue, cheek, salivary gland and the mandible. However, the higher concordance rate for other sites observed in our study agrees with report from a previous study by Tatli et al ⁶. Lesions usually located in areas such as the tongue, salivary gland and cheek mucosa have specific characteristics for recognition which may explain the high concordance rates.

The gender characteristics showed slightly higher concordance rates for the lesions in female patients when compared with male patients in this study. This is contrary to reports from the study by Tatli et al, ⁶ which shows a higher concordance among males. The slightly higher concordance rates for the lesions in female patients could be attributed to better health awareness by female patients when compared to males ¹⁰. Female patients tend to present earlier for diagnosis which may make diagnosis simpler compared to cases of late presentation, which may be more challenging to diagnosis by the clinician (surgeon) and oral and maxillofacial pathologist.

Sole reliance on clinical diagnosis by clinicians for patient management is inappropriate because there would be a high chance for erroneous diagnosis as demonstrated in this study with 35.5% of cases of clinical misdiagnosis. An

early and accurate diagnosis is extremely essential for successful patient management. It is worth noting that routine histopathological diagnosis of biopsied orofacial diseases is necessary for the detection of early malignancies. As general dental practitioners/general dentists and other dental specialists are qualified to perform routine biopsies for submission to a qualified oral and maxillofacial pathologist,⁸ they should not base their diagnosis only on clinical impressions, but in addition, they must carry out routine biopsy for histopathological examinations were applicable.

Good pathology support is however vital and should ideally be publicized and adequately made available to the general dentists. There is a need for continuous training in recent clinical and histopathological diagnostic techniques for both general and specialist dental practitioners among Nigerians. The importance of the provision of comprehensive and appropriate postgraduate training courses on oral diagnoses, oral medicine and histopathological diagnostic procedures for the dentist cannot be overemphasized. In addition, the cost for orofacial biopsy may need to be revised to make orofacial biopsy services affordable to patients.

In conclusion, the rate of clinical misdiagnosis among clinicians in LUTH though low can be improved. We recommend improvement in diagnostic skills in dental practice by continuous training in recent clinical and histopathological diagnostic techniques. Also, affordable and accessible pathology support services should be provided to general dentists / general dental practitioners and dental specialists in Nigeria.

Conflict of Interest: None declared

REFERENCES

- Oti AA, Donkor P, Obiri-Yeboah S, Yelibora M. Concordance between clinical and histopathological diagnoses at Komfo Anokye teaching hospital oral and maxillofacial unit. *Surgical Science*. 2013;4: 210-212
- Regezi. Odontogenic cysts, odontogenic tumors, fibrousseous, and giant cell lesions of the jaws. *Modern Pathology*. 2002; 15:331-341.
- Patel KJ, De Silva HL, Tong DC, Love RM. Concordance between Clinical and Histopathologic Diagnoses of Oral Mucosal Lesions. *Journal of Oral and Maxillofacial Surgery* 2011; 69: 125-133.
- Hosainpour Jajarm H, Mohtasham N. A comparative study on the clinical diagnosis and histopathologic report of patients' undergone biopsy at Department of oral Medicine of Mashhad Dental School from 2002 until 2004. *J Dent Mashhad Uni*. 2006; 30:47-54.
- Ghasemimoridani S, Sazesh F, Mohtasham Z. Correlation between clinical and histopathologic diagnosis of oral lesions surgery in the city of Rasht. *J Islamic Dent Associate Iran*. 2005;2: 95-99
- Tatli U, Erdoğan Ö, Uğuz A, Üstün Y, Sertdemir Y, Damlar İ. Diagnostic concordance characteristics of oral cavity lesions. *The Scientific World Journal*. 2013 Dec 25; 2013.
- Seifi S, Hoseini S R, Bijani A. Evaluation of clinical versus pathological difference in 232 cases with oral lesion. *Caspian J Intern Med*. 2010; 1 (1) :31-35
- Williams HK, Hey AA, Browne RA. The Use by General Dental Practitioners of an Oral Pathology Diagnostic Service over a 20-Year Period: The Birmingham Dental Hospital Experience. *British Dental Journal*. 1997; 182: 424-429.
- Seoane J, Warnakulasuriya S, Varela-Centelles P, Esparza G, Dios PD, "Oral Cancer: Experiences and Diagnostic Abilities Elicited by Dentists in North-Western Spain. *Oral Diseases*. 2006; 12: 487- 492.
- Ajayi DM, Arigbede AO. Barriers to oral health care utilization in Ibadan, South West Nigeria. *African health sciences*. 2013; 12:507-13.